
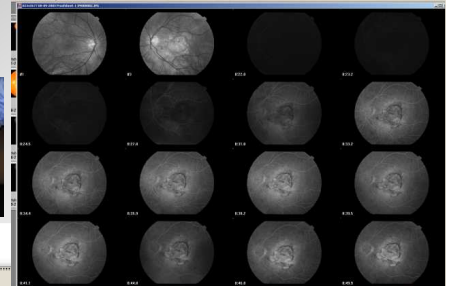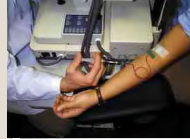
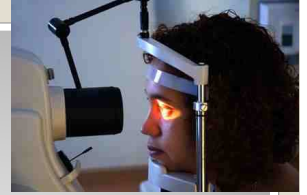

Change in drusen over one year

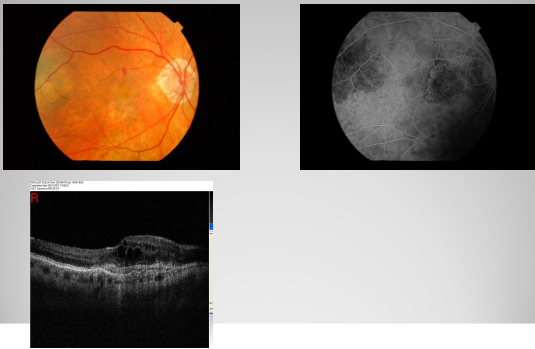


Fundus fluorescein angiography

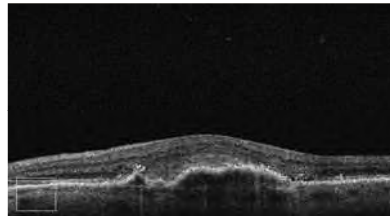
- Key investigation
- Looks at Retinal circulation



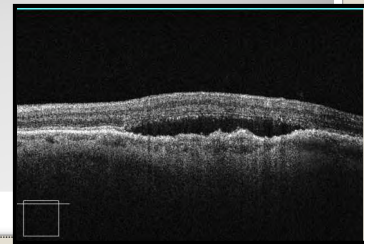
02510479 100% Classic Lesion



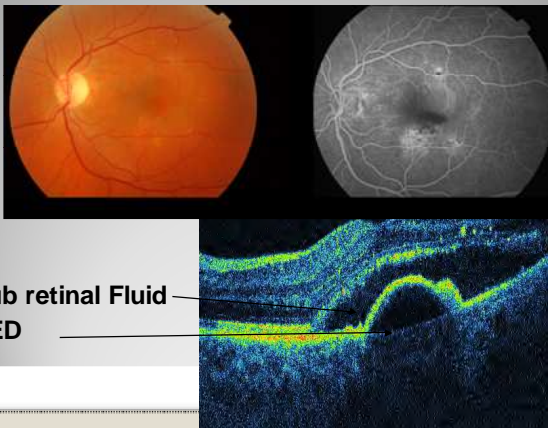
Wet AMD formation



**Rapid change
1 Week!
Warn Patients of
rapid Onset
DO not wait till next
appointment/exam**

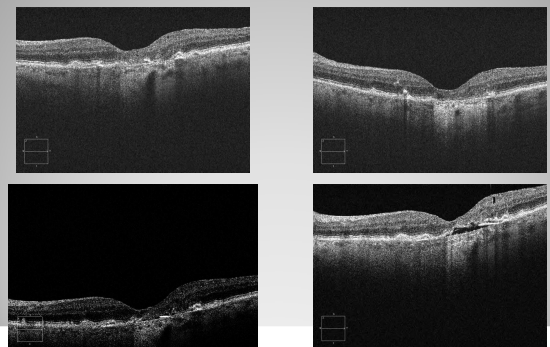


Wet AMD 6/12+2 62 F

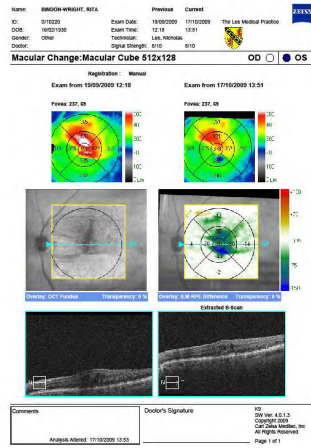
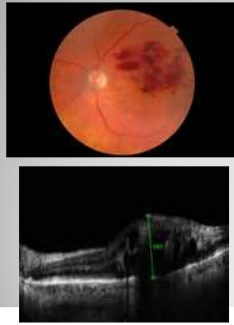

- Sub retinal Fluid
- PED

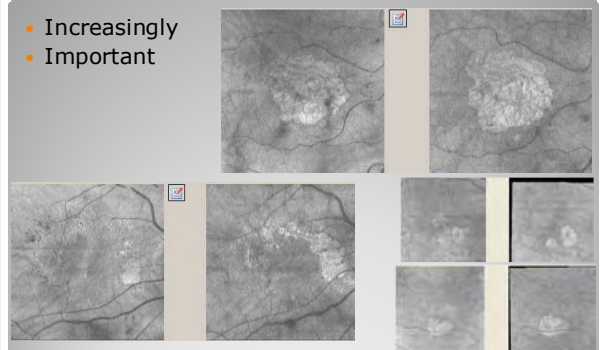
4 up comparisons between visits



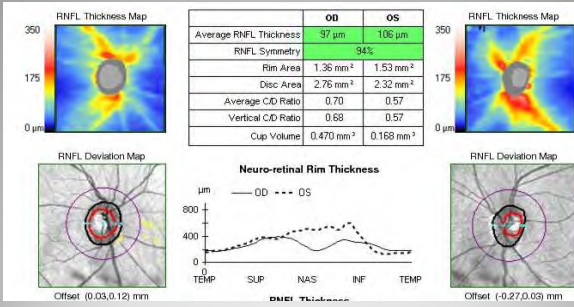
Zeiss Cirrus HD-OCT Change analysis



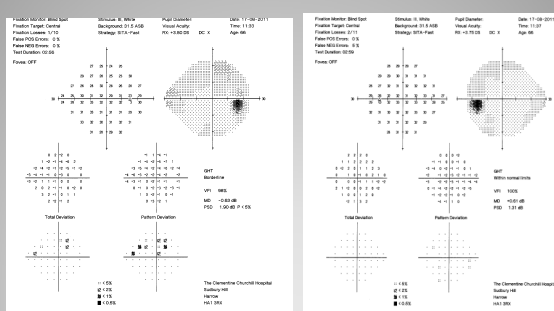
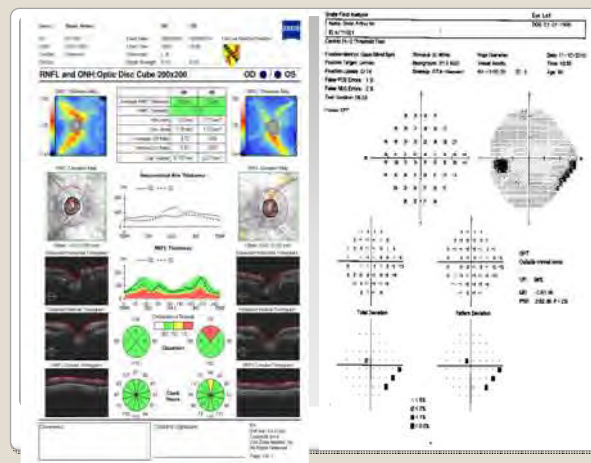
- Increasingly
- Important



Changes in Geographic atrophy Area measurements in next release

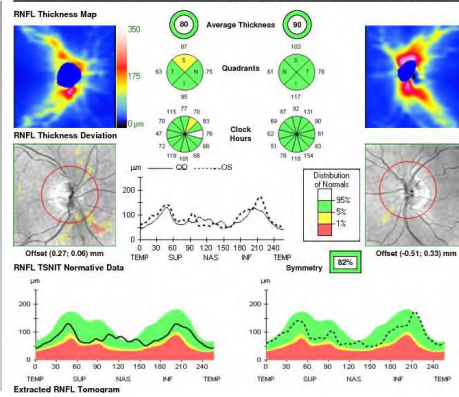


GDx – Optic Nerve Head examination.


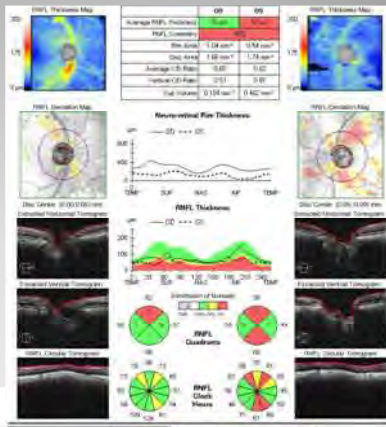


**IOP 42 Right 27
Subtle field changes in Ry**

RNFL Thickness Analysis: Optic Disc Cube 200x200

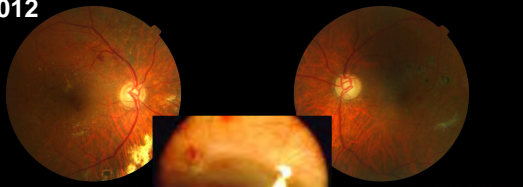


- 68 yr male
- 15 yrs diabetic
- IOP R15 L32
- Field defect
- Trabeculectomy my Left eye

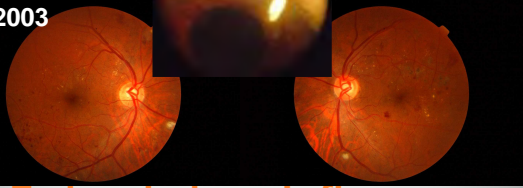


Fields

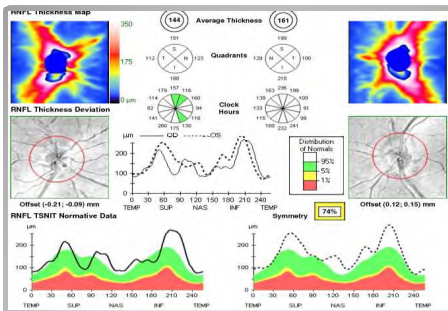
• 2012



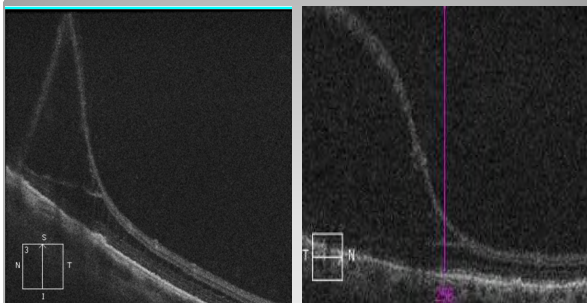
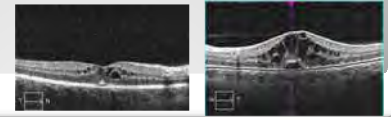
• 2003



Had Trabeculectomy Left eye
iop 23 now.

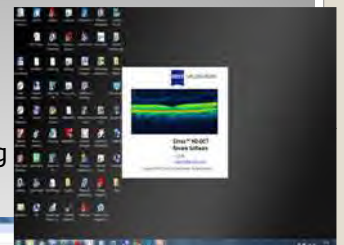

BIH
40
Overweight
Blond



Retinoschisis

- Review software
- Wired
- Wireless networking
- Remote networking

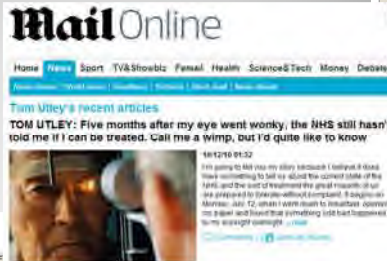

Networking



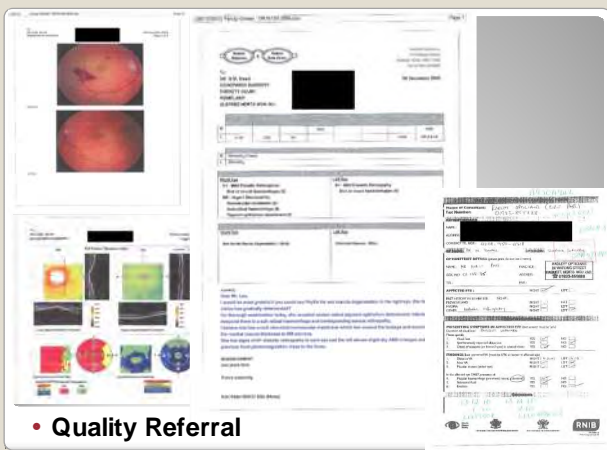
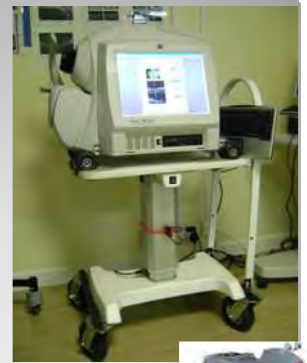Referrals

- Fax – Black images
- Paper to patient
- Email
- CD
- Internet Web hosting/Remote access



K9

- OCT Essential diagnostic tool
- Unavailability of Scans
 - NHS
 - Privately
- Compact, Sturdy Design
- Modified to be Mobile
 - Pneumatic Wheels
 - OCT & Table separate
 - Shogun Transport
 - Shopping Trolley design
 - Wireless Node
 - Wireless Review stations



- Quality Referral



This document was created with Win2PDF available at <http://www.win2pdf.com>.
The unregistered version of Win2PDF is for evaluation or non-commercial use only.
This page will not be added after purchasing Win2PDF.